

# Nuclear Medicine and Radiologic Imaging in Sports Injuries

Andor W.J.M. Glaudemans  
Rudi A.J.O. Dierckx  
Jan L.M.A. Gielen  
Johannes (Hans) Zwerver  
*Editors*

Glaudemans · Dierckx  
Gielen · Zwerver *Eds.*



Glaudemans  
Dierckx  
Gielen  
Zwerver  
*Editors*  
**Nuclear Medicine  
and Radiologic  
Imaging in Sports  
Injuries**

nsive book describes in detail  
edicine and radiology can  
of the sports medicine physi-  
g in precise diagnosis, clarifi-  
physiology, imaging of treat-  
and monitoring of rehabilita-  
l sections focus on nuclear  
radiologic imaging of injuries  
l face, spine, chest, shoulder,  
arm, wrist and hand, pelvic  
wer leg, ankle, and foot.  
iology of sports injuries fre-  
ntered in different regions  
cribed from the perspective  
y, and the potential diagnos-  
ment benefits offered by the  
ging modalities – SPECT/  
nd PET/MRI – are explained.  
ange of basic and general  
essed, including imaging of  
racteristic of specific sports.  
this book will promote inter-  
areness and communication  
e management of injured  
elite athletes.



Nuclear Medicine and  
Radiologic Imaging in Sports Injur



Wes O. Zimmermann, Peter H. Seidenberg,  
and Yogesh V. Kolwadkar

## Contents

31.1	Introduction .....	690
31.1.1	Epidemiology .....	691
31.2	Medial Tibial Stress Syndrome .....	691
31.2.1	Epidemiology .....	691
31.2.2	Etiology .....	692
31.2.3	Biomechanics and Risk Factors .....	692
31.2.4	Clinical Presentation .....	693
31.2.5	Imaging .....	693
31.2.6	Treatment .....	694
31.3	Stress Fractures .....	695
31.3.1	Etiology .....	695
31.3.2	Clinical Presentation .....	696
31.3.3	Imaging .....	696
31.3.4	Treatment .....	697
31.3.5	Prevention .....	697
31.4	Chronic Exertional Compartment Syndrome .....	698
31.4.1	Etiology .....	698
31.4.2	Clinical Presentation .....	699
31.4.3	Diagnostic Investigation .....	699
31.4.4	Treatment .....	701

W.O. Zimmermann, MD (✉)

Royal Dutch Army, Department of Sports Medicine, Utrecht, The Netherlands

Uniformed Services University of the Health Sciences, Bethesda, Maryland, USA

e-mail: wo.zimmermann@mindspring.com

P.H. Seidenberg, MD, FAAP, FACSM

Sports Medicine, Department of Orthopaedics and Rehabilitation, Penn State Hershey Bone and Joint Institute – State College, Penn State University, University Park, PA, USA

Y.V. Kolwadkar, MD, MRCS, MCh, MS

Private Practice Orthopaedist, Coffeyville Regional Medical Center, Coffeyville, KS, USA



31.5 Popliteal Artery Entrapment Syndrome.....	702
31.5.1 Etiology.....	702
31.5.2 Clinical Presentation.....	703
31.5.3 Diagnostic Imaging.....	703
31.5.4 Treatment.....	704
Conclusion.....	704
References.....	704

### Abstract

Lower leg pain and injury is a common occurrence in athletes that has been described in the medical and athletic literature. The various pathoanatomic processes, which could present as lower leg pain in the athlete, include medial tibial stress syndrome (MTSS), chronic exertional compartment syndrome (CECS), stress fracture, tendinopathy, nerve entrapment syndromes, vascular syndromes, and muscle injuries. The etiopathogenesis and clinical presentations of these conditions are described, and a brief account of diagnostic studies and treatment options is discussed.

### Abbreviations

AMA	American Medical Association
CECS	Chronic exertional compartment syndrome
EMG	Electromyography
ERLP	Exercise-related leg pain
MRI	Magnetic resonance imaging
MTSS	Medial tibial stress syndrome
NIRS	Near-infrared spectrometry
PAES	Popliteal artery entrapment syndrome
PNI	Peripheral neurogenic inflammation
SPECT	Single-photon emission computed tomography

### 31.1 Introduction

Lower leg pain and injury is a common occurrence in athletes that has been described in the medical and athletic literature as early as 1913. Over time, this pain has received multiple nomenclatures, including spike soreness, shin splints, posterior medial pain, and exercise-related leg pain (ERLP). The various pathoanatomic processes which could present as lower leg pain in the athlete include medial tibial stress syndrome (MTSS), chronic exertional compartment syndrome (CECS), stress fracture, tendinopathy, nerve entrapment syndromes, vascular syndromes, and muscle injuries. Of these, MTSS, stress fractures, and CECS are the most likely in an

athletic followed by nerve entrapment and vascular etiologies (Chanton and Solcher 1994; Edwards et al. 2005). Today, the lay person often refers to all of the above as simply "shin splints." The American Medical Association seems to lend credence to this concept and defines a shin splint as "pain and discomfort in the leg from repetitive running on a hard surface or forcible excessive use of foot flexors." However, it is the job of the astute clinician to differentiate the true etiology of the leg pain, thereby allowing more efficient treatment and return to activity. It is an additional challenge that several pathologies may coexist in the lower limb (Zimmermann 2013a; McCroly 2000).

#### 31.1.1 Epidemiology

Even though lower leg pain is commonly experienced in athletes, there have been few studies investigating the epidemiology of these injuries. It appears to be most frequent in runners; however, other sports also at risk include basketball, gymnastics, soccer, field hockey, dance, and basic military training (Yates and White 2004). The overall incidence of injury varies from 13 to 50 %, depending on the study and sport involved (Clement et al. 1981; Reinking 2006).

#### 31.2 Medial Tibial Stress Syndrome

MTSS presents as diffuse pain along the posteromedial aspect of the tibia. This complex syndrome has been referred to by many names based on the investigators' proposed etiology which include shin splints, soleus syndrome, medial tibial syndrome, tibial stress syndrome, posterior tibial syndrome, and periostitis (Stocum 1967; Puranen 1974; Clement et al. 1981; Mubarak et al. 1982; Holder and Michael 1984; Michael and Holder 1985).

The term medial tibial stress syndrome, as coined by Drez, is a condition which causes pain in the posteromedial aspect of the distal third of the tibia (Mubarak et al. 1982). At that time, it was suggested that periostitis was an essential etiology of MTSS. However, later histologic studies refuted these claims (Johnell et al. 1982). In addition, nuclear medicine investigations were consistent with the histologic findings. A true inflammatory process would show increased perfusion and blood pool on the first two phases of a bone scan, yet this is not the case in MTSS. Instead, the increased uptake is demonstrated in the late phase, suggesting a more metabolic cause (Rupani et al. 1985).

##### 31.2.1 Epidemiology

It has been difficult to determine the precise incidence of MTSS because of the varied and inconsistent terminology. Reports range from 4.1 to 35 % (Andrish et al. 1974; Yates and White 2004).



### 31.2.2 Etiology

Though the anatomic site in MTSS is known, the exact pathophysiology leading to the syndrome is still debated. Based on location of the pain, initially the tibialis posterior muscle was implicated as the cause (James et al. 1978; Saxena et al. 1990). However, subsequent anatomic studies demonstrated that the origin of the tibialis posterior muscle is much more lateral than originally thought, thereby eliminating it as the source of pain (Michael and Holder 1985).

More recently the fascial insertion for the soleus has been implicated (Bouche and Johnson 2007; Stuckley et al. 2009). Holder and Michael are credited to first point out the characteristic abnormality on the triple-phase bone scan where there was diffuse increased uptake on the posteromedial tibia only on the late phase of the scan (Holder and Michael 1984). Later, in cadaveric and EMG studies, they discovered that this area corresponded to the fascial insertion for the soleus called soleus bridge. Other studies pointed instead to the flexor digitorum longus (FDL) as a potential source as it appears to have a similar distribution of origin as the soleus (Garth and Miller 1989; Beck and Osternig 1994).

However, the most accepted etiology of MTSS is the traction theory. The medial portion of the soleus must contract eccentrically during the stance phase when the foot moves from supination to pronation. This results in increased stress at the fascial insertion for the soleus and disrupts the Sharpey's fibers, thereby producing MTSS (Michael and Holder 1985).

### 31.2.3 Biomechanics and Risk Factors

Apart from the traction explanation, many other theories have been put forward to explain MTSS. Another explanation is that repeated bending or bowing causes MTSS similar to a stress fracture. The point of the most profound bending is at the site where the tibia is narrowest, the junction of the mid- and distal thirds (Milgrom et al. 1989). The evidence to this theory was provided by Franklyn et al. in a cohort study. They showed that subjects with MTSS and tibial stress fractures were less adapted than aerobic controls to axial loading, torsion, and maximum and minimum bending rigidity (Franklyn et al. 2008). Further support to this hypothesis is provided by Magnusson who demonstrated that MTSS is associated with low regional bone mineral density (Magnusson et al. 2001).

Excessive foot pronation is the front-runner as a risk factor for MTSS. Bennett et al. reported a positive correlation between navicular drop used as a measure of pronation and incidence of MTSS (Bennett et al. 2001). Excessive pronation of the foot combined with repetitive impact activity has been implicated (Viitasalo and Kivist 1983; Messier and Pitatala 1988; Sommer and Vallentyne 1995). Viitasalo et al. found in a cinematographic analysis of runners that individuals with MTSS had a greater degree of pronation than control subjects who did not have MTSS (Viitasalo and Kivist 1983). Messier et al. reconfirmed the above finding in their cinematographic anthropometric study. In addition to greater maximum pronation, subjects with MTSS also demonstrated increased maximum velocity of pronation (Messier

and Pitatala 1988). Varus forefoot and hindfoot abnormalities have also been associated with this syndrome (Sommer and Vallentyne 1995).

Multiple risk factors are considered significant in the development of MTSS. In addition to excessive pronation, these include female sex, BMI greater than 21, previous history of MTSS, increased hip rotation, and small calf girth (Burne et al. 2004; Yates and White 2004; Plisky et al. 2007; Hubbard et al. 2009; Moen et al. 2012a). Other risk factors implicated include increase in running intensity, longer running distance, change in running shoes, and running on different terrain, but they are not supported by appropriate evidence (Beck 1998; Kortebein et al. 2000).

### 31.2.4 Clinical Presentation

#### 31.2.4.1 History

The most common complaint is a dull aching pain along the posteromedial aspect of the distal tibia. Initially, the pain usually occurs at the beginning of the run and resolves with continued exercise, only to recur later at the end of the workout. Eventually, the pain does not subside during the exercise and will only be relieved with rest. With continued exercise, the pain may sharpen during exercise and even persist at rest. However, there are no complaints of paresthesias. The patient may give history of abrupt increase in frequency, duration, or intensity of training. A recent change in workout terrain or shoes may also be elicited.

#### 31.2.4.2 Physical Examination

There typically will be diffuse tenderness along the posteromedial tibia involving the most distal 1/3 of the posterior medial tibial border (Yates and White 2004). Palpable pain locations in the muscles may be attributed to trigger points and/or peripheral neurogenic inflammation (PNI) (Zimmermann 2013b). Occasionally, there may be evidence of swelling or warmth in the region (Clanton and Solcher 1994; Fredericson et al. 1995). Less commonly, discomfort could be reproduced on stretching or contraction of the soleus muscle (Barry and McGuire 1996). The muscle could be loaded in different ways to reproduce the symptoms. These maneuvers include forced passive dorsiflexion, active plantar flexion against resistance, one-/two-legged standing toe raises, or one-/two-legged standing hop (Clement 1974; James et al. 1978).

Careful evaluation of foot position for hyperpronation and subtalar valgus should be performed. Individuals with MTSS have greater subtalar motion as compared to controls. A standing foot angle of  $<140^\circ$  is also associated with MTSS (Stocum 1967; Sommer and Vallentyne 1995).

### 31.2.5 Imaging

The necessity of imaging studies in the setting of a thorough history and examination is at best questionable as the diagnosis is more clinical than radiological. However, imaging could be sought to differentiate from other entities, especially



stress fracture. Plain radiographs are of little help in MTSS (Anderson et al. 1997; Magnusson et al. 2001; Aoki et al. 2004). Infrequently cortical hypertrophy may be noted (Batt et al. 1998). If any other findings such as scalloping, subperiosteal lucency, or a black line are seen, a stress fracture should be suspected.

A triple-phase bone scan is by far the most sensitive test for MTSS (Gaeta et al. 2005). It was first described by Holder and Michael and shows diffuse increase in uptake in the delayed phase along the posteromedial tibia (Holder and Michael 1984). The bone scan is also helpful to differentiate MTSS from the stress fracture. Medial and lateral spot views are required to clearly delineate the region of uptake. A limitation of the triple-phase bone scan is that it lacks specificity (Batt et al. 1998). Adding SPECT-CT to the late phase may help to increase the specificity.

MRI scan also has been shown to have a high sensitivity and specificity (Batt et al. 1998; Gaeta et al. 2005). MRI demonstrates diffuse abnormalities adjacent to the insertion of all the deep flexor compartment muscles. The other MRI findings reported include increased periosteal fluid and bone marrow edema (Anderson et al. 1997; Matitia et al. 1999). Fredericson et al. developed a grading system for stress reaction in runners based on clinical findings, bone scan, and MRI and concluded that there is no correlation between bone scintigraphy and MRI findings, which was later refuted by another study (Fredericson et al. 1995; Batt et al. 1998).

High-resolution computed tomography is another modality that has been evaluated. It demonstrated posteromedial cortical osteopenia in patients with MTSS with a sensitivity of 42 % and specificity of 100 % (Gaeta et al. 2006).

Despite the imaging modalities available, differentiating between an early stress fracture and MTSS is still a radiologic challenge.

### 31.2.6 Treatment

Initial management of MTSS usually involves relative rest. Specifically, running activity should be avoided completely, or the intensity and duration should be drastically reduced so that pain scores do not exceed 4 out of 10 on a self-scoring scale.

If the pain is brought on by activities of daily living, a period of non-weight bearing is advisable which should be continued until the patient is pain-free. Cross-training exercises such as swimming, cycling, or water running should be utilized to maintain cardiorespiratory fitness of the athlete. Other modalities such as cryotherapy, ice massage, phonophoresis, and bone stimulation have been advocated without any evidence as to efficacy of such treatment (Kortebein et al. 2000). Bracing on its own has shown no additional value (Moen et al. 2010). Compression sleeves do not improve time to onset of symptoms in patients with MTSS (Zimmermann 2013a), but they are appreciated by patients for their sense of support and comfort (Moen et al. 2012b; Zimmermann 2013a).

Adequate calcium balance and vitamin D optimization is recommended, especially in females. As MTSS is not an inflammatory disorder, routine and prolonged use of NSAIDs is not warranted. Acetaminophen is advised if analgesia is desired.

If required, correction of malalignment with appropriate orthotics is attempted (Loudon and Dolphino 2010). Once pain-free, the training is gradually increased in duration and intensity, progressing at the rate of 10 % per week.

Two studies reported good results with ESWT for recalcitrant cases (Rompe et al. 2010; Moen et al. 2012b). Nissen et al. investigated low-energy laser treatment for MTSS and found no statistical difference between those treated with the laser and those with placebo (Nissen et al. 1994). In recalcitrant cases, surgical procedures such as fasciotomy of the posteromedial superficial and deep fascia or perios-teal strip excision along the involved tibial border could be pursued, but the results are modest (Wallensten 1983).

Athletes and coaches should be made aware of the preventative measures for MTSS to include correction of improper running technique, maintenance of strength and flexibility, changing of footwear after every 300 miles, shock-absorbing insoles, and proper training programs (Beck 1998).

### 31.3 Stress Fractures

Stress fractures of the lower extremity account for up to 80 % of all stress fractures (Brewer and Gregory 2012). The tibia is the most common site (23.6 %). The other bones include the tarsal navicular (17.6 %), metatarsal (16.2 %), fibula (15.5 %), femur (6.6 %), and pelvis (1.6 %) (Bruckner et al. 1996). Persons who participate in repetitive high-intensity training such as athletes and military recruits are more likely to suffer from stress fractures. Recreational runners who run at least 25 miles per week are also likely to suffer from stress fractures. Also at increased risk are athletes in soccer, track and field, and dancing (Bennell and Bruckner 1997). Women are more at risk than men to develop stress fractures (Matheson et al. 1987).

#### 31.3.1 Etiology

Stress fractures are caused by repetitive loading with resulting bony microfracture. Imbalance in bone turnover with lagging bone production could also potentiate a stress fracture. This is especially found in the setting of sudden change in intensity, duration, or frequency of training (Boden et al. 2001). Another contributory factor could be muscle fatigue whereby the muscles fail to provide adequate shock absorption and thus allow more forces to be delivered to the bone (Meyer et al. 1993). Other possible factors implicated include poor nutrition, hormonal imbalance, and metabolic disorders, particularly in the female athletes (Bennell et al. 1999).

Although many other variables like age, bone mineral density, limb alignment, limb length discrepancy, and alcohol consumption have been suggested as risk factors, definitive evidence is lacking.



### 31.3.2 Clinical Presentation

The initial presentation is gradual-onset activity-related pain that initially improves with rest. With continued chronicity and development of fracture, the pain is constant and ultimately present with all weight-bearing activities. The patient may admit to sudden increase in duration or intensity of training. Other considerations include general nutritional status and dietary and menstrual history.

On examination, focal tenderness is elicited over the area of pathology. As the tibia is the most common bone fractured, both stress fracture and MTSS present with similar local findings. However, the pain in MTSS is more diffuse as compared to the focal tenderness in stress fracture. Edema may not be evident. The single-leg hop test is an often used physical exam test for stress fractures. Another diagnostic test used is the tuning fork test, that is, applying a vibrating tuning fork to the fracture site to elicit pain (Lesho 1997). A fulcrum test or twisting force may also reproduce the pain as well as compression of tibiofibular syndesmosis. The examination should also include assessment of limb length, alignment, and muscle tone.

The common differential diagnosis in the leg includes MTSS, CECS, tendinopathies, and neurovascular syndromes. It is also important to rule out malignancies, such as Ewing's sarcoma and osteosarcoma (Fayad et al. 2005).

### 31.3.3 Imaging

Plain radiographs are the first line of investigation because of availability and low cost. They have, however, a sensitivity of only 15 % in the first week, which is increased to up to 70 % at 3 weeks (Boden and Osbahr 2000). The x-ray may show direct evidence of the fracture with lucency or more commonly indirect evidence in the form of periosteal reaction, cortical changes with initial decreased density (gray cortex), and sometimes callus formation or endosteal thickening and sclerosis (Boden et al. 2001; Ohta-Fukushima et al. 2002).

CT scan has shown less sensitivity than bone scan or MRI and hence has been superseded by the latter for diagnosing stress fractures (Gaeta et al. 2005; Groves et al. 2005).

Triple-phase bone scintigraphy is a highly sensitive investigation to differentiate between MTSS and stress fracture (Gaeta et al. 2005). The former shows diffuse uptake in the delayed phase, while the latter shows localized tracer activity in all the three phases. However, scintigraphy can be falsely positive in cases of infection and bone tumor (Fayad et al. 2005).

More recently MRI has replaced scintigraphy as the investigation of choice despite cost and availability. It has sensitivity nearly equal to scintigraphy. The MRI usually shows bone edema at the site of fracture. MRI may also help in identifying reactive bone remodeling (interpreted as early stress injuries). MRI has the additional advantage of being able to evaluate surrounding soft tissues (Gaeta et al. 2005).

Although musculoskeletal ultrasound has shown much promise in soft tissue work, its use for the diagnosis of stress fracture is limited. One small study found that ultrasonography had a sensitivity of 83 %, specificity of 75 %, a positive predictive value of 58.8 %, and a negative predictive value of 91.7 % for metatarsal fractures (Banal et al. 2009). More investigation is required prior to routine adoption of ultrasound in the diagnosis of bony stress injury.

### 31.3.4 Treatment

Initial management of most stress fractures is nonoperative. The specific management depends on the nature and location of the fracture. Fibular and posteromedial tibia fractures are considered low risk and can be treated with less aggressive means. Anterior tibia and malleolar fractures are categorized as high risk and should be aggressively managed with casting, non-weight bearing, and use of bone stimulation (Mollon et al. 2008). The healing time can vary from 4 to 12 weeks or even longer dependent upon the location. The treatment begins with relative rest and non-weight bearing in high-risk injuries. Predisposing factors if present, such as suboptimal nutrition and hormonal imbalance, should be corrected. Analgesia with acetaminophen is recommended for pain control; however, NSAIDs should be avoided considering their negative effect on bone healing in animal studies (Wheeler and Batt 2005).

The use of crutches, pneumatic compression walking boots, or stirrup bracing is recommended (Rome et al. 2005). The use of shoe lifts, footwear changes, or orthotics may be necessary if limb malalignment is present.

The most common site for tibia fracture is on the posteromedial cortex. It is treated by relative rest followed by gradual resumption of graded activity. The fracture may take 2–4 months to heal. A pneumatic brace can decrease the time to return to full activity (Swenson et al. 1997). Anterior tibial cortical fractures are more troublesome. Since they are on the tension side of the bone, they are more likely to end up into delayed or nonunion. They may entail the use of cast treatment for up to 6 months (Boden and Osbahr 2000). If conservative measures fail, surgical fixation with drilling, osteosynthesis, or intramedullary rod may be required (Orava et al. 1991; Lassus et al. 2002).

### 31.3.5 Prevention

Preventative measures include modification of training intensity and formulation of individual training schedules for each athlete. Emphasis should be on proper nutrition maintenance and supplementation if required. Shock-absorbing insoles have been shown to be effective in decreasing lower extremity fractures in military recruits (Rome et al. 2005; Shaffer and Uhl 2006).



### 31.4 Chronic Exertional Compartment Syndrome

CECS is a less common cause of leg pain, but some studies of referral centers have reported an incidence as high as 27–33% (Styf 1988; Clanton and Solcher 1994). It is defined as reversible ischemia occurring within a closed fibro-osseous space, which leads to decreased tissue perfusion and ischaemic pain. It is most commonly seen in runners but can also occur in sports requiring repetitive jumping and cutting such as basketball, soccer, and field hockey and basic military training. One of the first reports was described in 1956 by Mavor, when he described the case of a soccer player who was relieved with a fasciotomy (Mavor 1956). CECS most commonly occurs in the lower leg but has also been reported in the thigh and forearm (McDonald et al. 2006).

The anterior compartment is most commonly involved (45%) followed by the deep posterior compartment (40%). Infrequently affected are the lateral (10%) and superficial posterior compartments (5%) (Edwards and Myerson 1996). Symptoms are bilateral in 50–70%, and both sexes are equally affected (Touliopoulos and Hershman 1999; Glorioso and Wilkens 2001).

#### 31.4.1 Etiology

The lower leg is divided into four compartments: anterior, lateral, superficial posterior, and deep posterior. The anterior compartment contains the anterior tibial vessels and the deep peroneal nerve, while the deep posterior compartment contains the posterior tibial nerve and posterior tibial artery. The remaining two compartments only have major nerves. The lateral compartment has the superficial peroneal nerve, and the superficial posterior compartment contains the sural nerve.

The pathophysiology of CECS is multifactorial. Broadly these factors can include normal muscle swelling that occurs with activity, constrains of a fixed muscular compartment, abnormally thickened fascia, muscle hypertrophy in response to resistance training, and dynamic contraction patterns during gait (Brennan and Kane 2003). With physical activity, the muscle volume increases up to 20% due to increase in blood flow (Lundvall et al. 1972; Edwards and Myerson 1996; Glorioso and Wilkens 2001). If the fascia is noncompliant, the resultant volume expansion leads to an increase in the pressure within the compartment. After a certain threshold, the pressure becomes so much as to impede venous return and arterial blood flow. This results in focal ischemia and trapping of metabolic excretions within the compartment, leading to pain. This pain is only relieved when the compartment pressure decreases in the hours after the activity has been terminated.

Various anatomic variants also play an important role in the causation of CECS. These include conditions like fascial defects, preponderance of lower capillary density among predisposed individuals, and arterial regulations and blood flow (Fronek et al. 1987; Edmundsson et al. 2010). Creatine supplementation has also been postulated to contribute CECS (Glorioso and Wilkens 2001).

#### 31.4.2 Clinical Presentation

Patients classically have pain during exercise or activity which is described as a dull, cramping, or burning sensation over the involved compartment which may persist even after the activity has ceased. There is almost always no rest pain. Typically the patient is a young runner who experiences recurrent pain after exercise at a reproducible point during exercise (Jones and James 1987). They may complain of numbness or weakness in the lower leg. As the chronicity of the condition increases, the period of time to onset of symptoms during exercise shortens.

High resting muscle tone and fascial herniations indicate that pressures during exercise may surpass pathological levels.

It is essential to provoke the patient's complaints with an exercise test. Zimmermann proposes a standardized treadmill running test with a pain scoring system that allows differentiation of several diagnoses per patient (Zimmermann 2012) (Fig. 31.1).

Repeat physical examination is warranted after a bout of provocative physical activity. One may find evidence of paresthesias, giving an indication as to which compartment is involved. Fascial herniations may be visualized. On palpation, the affected compartment will have increased tightness. In severe cases, muscle weakness and atrophy may be evident (George and Hutchinson 2012). In exceptional cases, CECS may progress into acute compartment syndrome if intensive sports participation is not stopped. Patients should be advised of this rare complication.

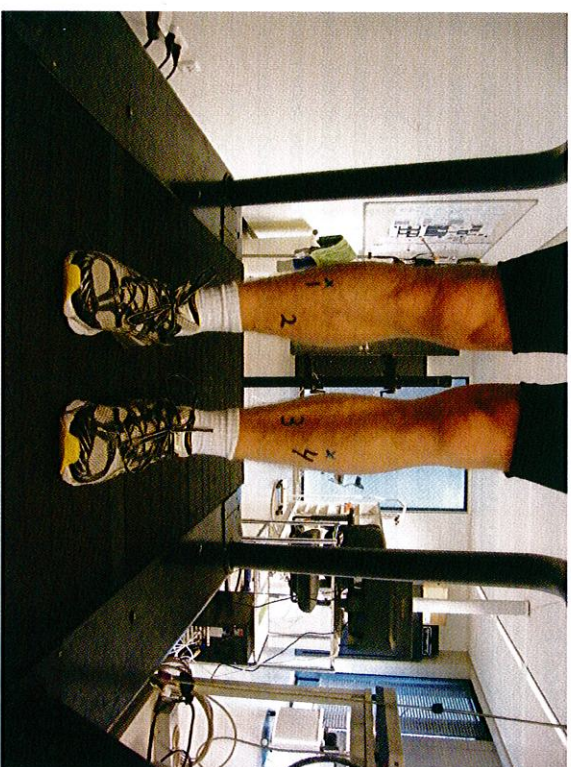
#### 31.4.3 Diagnostic Investigation

Radiographs are unremarkable in patients with CECS. Compartment pressure testing is the gold standard for diagnosis. Post-exertional measures are required (Awleid et al. 2012). Pre-exertional measures may provide useful additional information (Paik et al. 2013). All four compartments should be routinely measured to prevent risk of recurrence and surgical failure. Many different methods have been described to measure the compartment pressure including slit catheter (Rorabeck et al. 1981), needle manometer (Whitesides et al. 1975), wick catheter (Mubarak et al. 1976), microcapillary infusion (Styf and Korner 1986), and microtip pressure method (McDermott et al. 1982). In a laboratory model, the arterial line manometer and Stryker devices (Fig. 31.2) are the most accurate (Boody and Wongworawat 2005). However, this has yet to be confirmed *in vivo*.

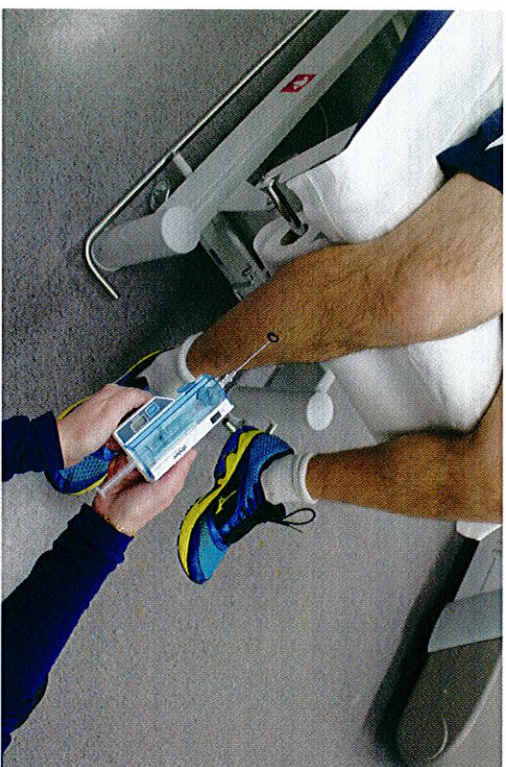
The criteria by Pedowitz are generally used in the diagnosis of CECS (Pedowitz et al. 1990). One of the following criteria must be present in addition to proper history and physical examination:

- Resting pressure  $\geq 15$  mmHg
- 1 min postexercise pressure  $\geq 30$  mmHg
- 5 min postexercise pressure  $\geq 20$  mmHg





**Fig. 31.1** Lower leg pain profile, pain scores in 4 regions, Zimmermann (2012)



**Fig. 31.2** Stryker intracompartmental pressure monitor

Whitesides proposed an alternate criterion, with a pressure increase within 20 mmHg of the diastolic blood pressure considered diagnostic (Whitesides and Heckman 1996).

Table 31.1 lists several other reported diagnostic criteria for CECS. It is important to note that intracompartmental pressure measurements are influenced by ankle

**Table 31.1** Diagnostic criteria for chronic exertional compartment syndrome

Criteria	Pre-exercise	1 min postexercise	5 min postexercise
Pedowitz	≥15	≥30	≥20
Veith	>12	>30	>20
Hutchinson and Ireland	>10	–	>25
Verleisdonk	–	≥35	–

All measurements expressed in mmHg (Veith et al. 1980; Pedowitz et al. 1990; Hutchinson and Ireland 1994; Verleisdonk 2002)

and knee position and muscular tension (Gershuni et al. 1984). Clinicians are recommended to use a protocol with standardized catheter depth, exercise type, intensity and duration, footwear, and equipment. It may be wise to raise diagnostic thresholds to improve test specificity at the expense of sensitivity (Roberts and Franklyn-Miller 2012). Simultaneous intramuscular pressure and surface electromyography (EMG) measurement may prevent false diagnosis of CECS. The EMG detects remaining muscle contractions that elevate intracompartmental pressure (Zhang et al. 2011).

These are all invasive approaches, and recently interest has been drawn toward noninvasive pressure monitoring with the use of near-infrared spectroscopy and MRI. Near-infrared spectroscopy shows the deoxygenation of muscles during exercise and delayed reoxygenation postexercise in patients with CECS (Breit et al. 1997; Mohler et al. 1997; Zhang et al. 2001; van den Brand et al. 2004; Zhang et al. 2012). MRI shows increased signal intensity in the involved compartment on T2-weighted sequence during exercise. If the compartment fails to return to baseline appearance within 25 min after exercise, it is considered diagnostic (Amendola et al. 1990; Verleisdonk et al. 2001). Other findings that could be seen on MRI are compartment bulging, effacement of fascial planes, convex deep fascial margins, and muscle herniation through fascial defects (Bresler et al. 2012). The usefulness of MRI for diagnosis has been called into question by Andreisek who found no difference in MRIs of healthy versus confirmed CECS patients at 3, 6, 9, 12, and 15 min postexercise (Andreisek et al. 2009).

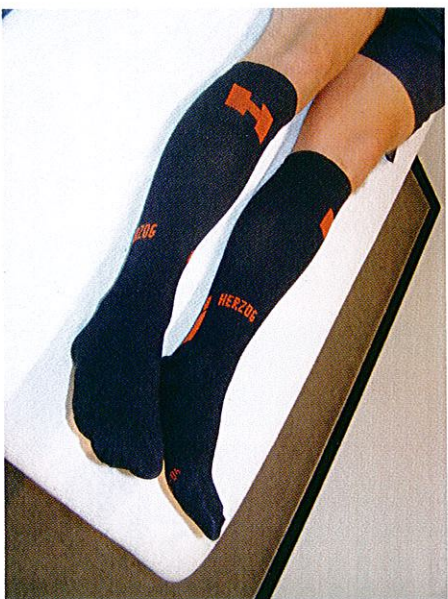#### 31.4.4 Treatment

Nonsurgical management of CECS is frequently ineffective. Micheli et al. assessed multiple modalities including ice, rest, electrostimulation, and stretching and found that only prolonged rest and activity cessation were effective (Micheli et al. 1999). Recently, promising results have been reported with changing running technique in patients with CECS of the anterior compartment (Diebal et al. 2012). Anterior compartment pressures are significantly influenced by landing style (Kirby and McDermott 1983).

The use of compression sleeves (Fig. 31.3) is counterproductive, as they are not tolerated by patients with affirmed CECS. The sleeves increase already high



**Fig. 31.3** Sport compression sleeves



intramuscular pressures and reduce the time of onset of complaints during exercise (Zimmermann 2013a).

Commonly, a fasciotomy of the involved compartment is required, which can be performed through an open subcutaneous manner or an endoscopic approach (Ota et al. 1999; Leversedge et al. 2002; Lohrer and Nauck 2007; Witstein et al. 2010). Consistent results are usually obtained after release of the anterior and lateral compartment (80 %) but not after release of the superficial and deep posterior compartment (50 %) (Howard et al. 2000; van Zoest et al. 2008). Fasciotomy is not without its short-term and long-term complications, which include hematoma formation, infection, scarring, venous thromboembolism, nerve injury, inadequate release, unrecognized nerve impingement (George and Hutchinson 2012), and venous insufficiency. Surgery for CECS reduces pain, but patients should be counseled that they may not return to their preinjury level of exercise or remain pain-free (Slimmon et al. 2002).

### 31.5 Popliteal Artery Entrapment Syndrome

Popliteal artery entrapment syndrome (PAES) is a rare entity but can be of devastating consequence if unrecognized and left untreated. The syndrome occurs most commonly in young active men (Stager and Clement 1999). The reported incidence is 0.2–3.5 % (Anil et al. 2011).

#### 31.5.1 Etiology

PAES commonly results from abnormal anatomic relationship between the popliteal artery and the surrounding musculofascial envelope (Lambert and Wilkins 1999; Stager and Clement 1999). Four types of PAES have been described and

classified according to Whelan-Rich (Love and Whelan 1965; Rich et al. 1979). Type 1 occurs when the popliteal artery has a course medial to the medial head of the gastrocnemius muscle. In type 2, the arterial course is normal but the medial head of the gastrocnemius arises from abnormal lateral position. In type 3, there is an abnormal slip of the muscle that arises from the gastrocnemius and compresses the popliteal artery. In type 4, there is an abnormal fibrous band or the popliteus muscle itself compresses the popliteal artery. Type 5, though not originally reported by Whelan, refers to involvement of the popliteal vein. Type 6 is when the anatomy is normal, but there is hypertrophy of the surrounding musculature compressing the artery (functional PAES) (Turnipseed 2009). In addition to the above, repeated trauma to the artery can result in damage to the arterial wall resulting in atherosclerosis or possible thrombus formation. Moreover, there is a possibility of formation of aneurysm distal to the constriction with resultant embolization of the thrombi.

Other potential vascular causes in athletes of lower limb pain include intimal hyperplasia, popliteal artery aneurysm, peripheral arterial dissections, and cystic adventitial disease (Pham et al. 2007).

#### 31.5.2 Clinical Presentation

The typical history is of claudication pain in a young athlete, which may be associated with paresthesias. The pain is brought on by activity at a predetermined distance and usually relieved with rest. Rarely, there may be discoloration of the foot or toes. There is no pain at rest.

Physical examination may reveal abnormal pulses, fullness from an aneurysm, or a normal exam. In the latter case, it may be prudent to palpate the dorsalis pedis and/or tibial arterial pulse and compare pulses when the ankle is in neutral position, maximal dorsiflexion, and maximal plantar flexion. In suspected cases, investigation for an abnormal ankle brachial pressure index could be pursued (normal >0.9).

#### 31.5.3 Diagnostic Imaging

Direct angiography is the gold standard to diagnose PAES. Though angiography can successfully diagnose the arterial constriction, it can shed little light on the exact cause of the stenosis. This is where MR angiography supersedes conventional angiography in that abnormal muscle origin or accessory muscle head could be identified. Moreover, MRI can provide real-time images with the patient performing active dorsiflexion and plantar flexion. Contrast-enhanced MR is helpful in dealing with turbulence and flow patterns in an aneurysm and can successfully delineate the correct lumen of the artery (Elias et al. 2003). It is recommended that MR examinations should be done in a bilateral setting as bilateral involvement is seen in 30–60 % of the patients (Anil et al. 2011). Computed tomography angiography is advantageous as both extremities could be scanned simultaneously with a single bolus and it is faster than MR (Anil et al. 2011).



### 31.5.4 Treatment

The treatment is almost always surgical with the exact operation guided by the abnormality present. It could either take the form of surgical excision of the offending structure, venous bypass, or an interpositional graft. Other alternatives include endoluminal revascularization (Meier et al. 2010).

#### Conclusion

Lower leg pain is a common occurrence in athletes. To determine the true etiology, the astute clinician must perform a detailed history and physical examination. Adjunctive testing can assist in confirming the diagnosis. MTSS is the most common cause of exertional lower leg pain. The patient will have diffuse posterior medial tibial pain, whereas the discomfort of a stress fracture is more focal. CECS causes reproducible lower leg pain with tightness and associated neuropathic findings in the affected compartment. Exertional compartment testing is required for diagnosis. In contrast, popliteal artery entrapment syndrome results in exertional claudication and can be confirmed on functional MR angiography. The treatment for MTSS and stress fracture is typically conservative, while that of CECS and PAES often requires surgical intervention.

#### References

- Amendola A, Rorabeck CH, Velleit D, Vezina W, Rutt B, Nott L (1990) The use of magnetic resonance imaging in exertional compartment syndromes. *Am J Sports Med* 18(1):29–34
- Anderson MW, Ugalde V, Batt M, Gacayan J (1997) Shin splints: MR appearance in a preliminary study. *Radiology* 204(1):177–180
- Andrejsk G, White LM, Sussman MS, Langer DL, Patel C, Su JW, Haider MA, Stainsby JA (2009) T2\*-weighted and arterial spin labeling MRI of calf muscles in healthy volunteers and patients with chronic exertional compartment syndrome: preliminary experience. *AJR Am J Roentgenol* 193(4):W327–W333
- Andrich JT, Bergfeld JA, Walheim J (1974) A prospective study on the management of shin splints. *J Bone Joint Surg Am* 56(8):1697–1700
- Anil G, Tay KH, Howe TC, Tan BS (2011) Dynamic computed tomography angiography: role in the evaluation of popliteal artery entrapment syndrome. *Cardiovasc Intervent Radiol* 34(2):259–270
- Aoki Y, Yasuda K, Tohyama H, Ito H, Mirami A (2004) Magnetic resonance imaging in stress fractures and shin splints. *Clin Orthop Relat Res* April (421):260–267
- Aweid O, Del Buono A, Malliaras P, Iqbal H, Morrissey D, Matfulli N, Padhiar N (2012) Systematic review and recommendations for intracompartamental pressure monitoring in diagnosing chronic exertional compartment syndrome of the leg. *Clin J Sport Med* 22(4):356–370
- Banal F, Gandjbakhsh F, Foltz V, Goldeher A, Etcheperre F, Rozenberg S, Koeger AC, Bourgeois P, Fautrel B (2009) Sensitivity and specificity of ultrasonography in early diagnosis of metatarsal bone stress fractures: a pilot study of 37 patients. *J Rheumatol* 36(8):1715–1719
- Barry NN, McGuire JL (1996) Acute injuries and specific problems in adult athletes. *Rheum Dis Clin North Am* 22(3):531–549
- Batt ME, Ugalde V, Anderson MW, Shelton DK (1998) A prospective controlled study of diagnostic imaging for acute shin splints. *Med Sci Sports Exerc* 30(11):1564–1571
- Beck BR (1998) Tibial stress injuries. An aetiological review for the purposes of guiding management. *Sports Med* 26(4):265–279
- Beck BR, Ostering LR (1994) Medial tibial stress syndrome. The location of muscles in the leg in relation to symptoms. *J Bone Joint Surg Am* 76(7):1057–1061
- Bennell KL, Brukner PD (1997) Epidemiology and site specificity of stress fractures. *Clin Sports Med* 16(2):179–196
- Bennell K, Matheson G, Meeuwisse W, Brukner P (1999) Risk factors for stress fractures. *Sports Med* 28(2):91–122
- Bennett JE, Reinking MF, Pluemer B, Penzel A, Seaton M, Killian C (2001) Factors contributing to the development of medial tibial stress syndrome in high school runners. *J Orthop Sports Phys Ther* 31(9):504–510
- Boden BP, Osbahr DC (2000) High-risk stress fractures: evaluation and treatment. *J Am Acad Orthop Surg* 8(6):344–353
- Boden BP, Osbahr DC, Jimenez C (2001) Low-risk stress fractures. *Am J Sports Med* 29(1):100–111
- Boody AR, Wongworawat MD (2005) Accuracy in the measurement of compartment pressures: a comparison of three commonly used devices. *J Bone Joint Surg Am* 87(11):2415–2422
- Bouche RT, Johnson CH (2007) Medial tibial stress syndrome (tibial fasciitis): a proposed pathomechanical model involving fascial traction. *J Am Podiatr Med Assoc* 97(1):31–36
- Breit GA, Gross JH, Watenpaugh DE, Chance B, Hargens AR (1997) Near-infrared spectroscopy for monitoring of tissue oxygenation of exercising skeletal muscle in a chronic compartment syndrome model. *J Bone Joint Surg Am* 79(6):838–843
- Brennan FH Jr, Kane SF (2003) Diagnosis, treatment options, and rehabilitation of chronic lower leg exertional compartment syndrome. *Curr Sports Med Rep* 2(5):247–250
- Bresler M, Mar W, Toman J (2012) Diagnostic imaging in the evaluation of leg pain in athletes. *Clin Sports Med* 31(2):217–245
- Brewer RB, Gregory AJ (2012) Chronic lower leg pain in athletes: a guide for the differential diagnosis, evaluation, and treatment. *Sports Health* 4(2):121–127
- Brukner P, Bradshaw C, Khan KM, White S, Crossley K (1996) Stress fractures: a review of 180 cases. *Clin J Sport Med* 6(2):85–89
- Burne SG, Khan KM, Boudville PB, Mallett RJ, Newman PM, Steinman LJ, Thornton E (2004) Risk factors associated with exertional medial tibial pain: a 12 month prospective clinical study. *Br J Sports Med* 38(4):441–445
- Clanton TO, Solcher BW (1994) Chronic leg pain in the athlete. *Clin Sports Med* 13(4):743–759
- Clement DB (1974) Tibial stress syndrome in athletes. *J Sports Med* 2(2):81–85
- Clement DB, Taunton JE, Smart GW, McNicol KL (1981) A survey of overuse running injuries. *Phys Sportsmed* 9:47–58
- Diebal AR, Gregory R, Alitz C, Gerber JP (2012) Forefoot running improves pain and disability associated with chronic exertional compartment syndrome. *Am J Sports Med* 40(5):1060–1067
- Edmundsson D, Toolanen G, Thornell LE, Stal P (2010) Evidence for low muscle capillary supply as a pathogenic factor in chronic compartment syndrome. *Scand J Med Sci Sports* 20(6):805–813
- Edwards P, Myerson MS (1996) Exertional compartment syndrome of the leg: steps for expedient return to activity. *Phys Sportsmed* 24(4):31–46
- Edwards PH Jr, Wright ML, Hartman JF (2005) A practical approach for the differential diagnosis of chronic leg pain in the athlete. *Am J Sports Med* 33(8):1241–1249
- Elias DA, White LM, Rubenstein JD, Christakis M, Merchant N (2003) Clinical evaluation and MR imaging features of popliteal artery entrapment and cystic adventitial disease. *AJR Am J Roentgenol* 180(3):627–632
- Fayad LM, Kawamoto S, Kamel IR, Bluentke DA, Eng J, Frassica FJ, Fishman EK (2005) Distinction of long bone stress fractures from pathologic fractures on cross-sectional imaging: how successful are we? *AJR Am J Roentgenol* 185(4):915–924
- Franklyn M, Oakes B, Field B, Wells P, Morgan D (2008) Section modulus is the optimum geometric predictor for stress fractures and medial tibial stress syndrome in both male and female athletes. *Am J Sports Med* 36(6):1179–1189



- Fredericson M, Bergman AG, Hoffman KL, Dillingham MS (1995) Tibial stress reaction in runners. Correlation of clinical symptoms and scintigraphy with a new magnetic resonance imaging grading system. *Am J Sports Med* 23(4):472-481
- Fronck J, Mubarak SI, Hargens AR, Lee YF, Gershuni DH, Garfin SR, Akesson WH (1987) Management of chronic exertional anterior compartment syndrome of the lower extremity. *Clin Orthop Relat Res July* (220):217-227
- Gaeta M, Minuiti F, Scibano E, Ascenti G, Vinci S, Bruschetta D, Magaouda L, Blandino A (2005) CT and MR imaging findings in athletes with early tibial stress injuries: comparison with bone scintigraphy findings and emphasis on cortical abnormalities. *Radiology* 235(2):553-561
- Gaeta M, Minuiti F, Vinci S, Salamone I, D'Andrea L, Bitto L, Magaouda L, Blandino A (2006) High-resolution CT grading of tibial stress reactions in distance runners. *AJR Am J Roentgenol* 187(3):789-793
- Garth WP Jr, Miller ST (1989) Evaluation of claw toe deformity, weakness of the foot intrinsic, and posteromedial shin pain. *Am J Sports Med* 17(6):821-827
- George CA, Hutchinson MR (2012) Chronic exertional compartment syndrome. *Clin Sports Med* 31(2):307-319
- Gershuni DH, Yaru NC, Hargens AR, Lieber RL, O'Hara RC, Akesson WH (1984) Ankle and knee position as a factor modifying intracompartamental pressure in the human leg. *J Bone Joint Surg Am* 66(9):1415-1420
- Glorioso J, Wilkens J (2001) Exertional leg pain. In: O'Connor F, Wilder R (eds) *Textbook of running medicine*. McGraw-Hill, New York, pp 181-198
- Groves AM, Cheow HK, Balan KK, Housden BA, Bearcroft PW, Dixon AK (2005) 16-Detector multislice CT in the detection of stress fractures: a comparison with skeletal scintigraphy. *Clin Radiol* 60(10):1100-1105
- Holder LE, Michael RH (1984) The specific scintigraphic pattern of "shin splints in the lower leg": concise communication. *J Nucl Med* 25(8):865-869
- Howard JL, Mohrati NG, Wiley JP (2000) Evaluation of outcomes in patients following surgical treatment of chronic exertional compartment syndrome in the leg. *Clin J Sport Med* 10(3):176-184
- Hubbard TJ, Carpenter EM, Cordova ML (2009) Contributing factors to medial tibial stress syndrome: a prospective investigation. *Med Sci Sports Exerc* 41(3):490-496
- Hutchinson MR, Ireland ML (1994) Common compartment syndromes in athletes. Treatment and rehabilitation. *Sports Med* 17(3):200-208
- James SL, Bates BT, Osternig LR (1978) Injuries to runners. *Am J Sports Med* 6(2):40-50
- Johnell O, Rausing A, Wendeberg B, Westlin N (1982) Morphological bone changes in shin splints. *Clin Orthop Relat Res July* (167):180-184
- Jones DC, James SL (1987) Overuse injuries of the lower extremity: shin splints, iliothibial band friction syndrome, and exertional compartment syndromes. *Clin Sports Med* 6(2):273-290
- Kirby RL, McDermott AG (1983) Anterior tibial compartment pressures during running with rear-foot and forefoot landing styles. *Arch Phys Med Rehabil* 64(7):296-299
- Korthein PM, Kaufman KR, Bastford JR, Stuart MJ (2000) Medial tibial stress syndrome. *Med Sci Sports Exerc* 32(3 Suppl):S27-S33
- Lambert AW, Wilkins DC (1999) Popliteal artery entrapment syndrome. *Br J Surg* 86(11):1365-1370
- Lassus J, Tuulikoura I, Kontinen YT, Salo J, Santavirta S (2002) Bone stress injuries of the lower extremity: a review. *Acta Orthop Scand* 73(3):359-368
- Lesho EP (1997) Can tuning forks replace bone scans for identification of tibial stress fractures? *Mil Med* 162(12):802-803
- Levereddege FI, Casey PJ, Seiler JG 3rd, Xerogeanes JW (2002) Endoscopically assisted fasciotomy: description of technique and in vitro assessment of lower-leg compartment decompression. *Am J Sports Med* 30(2):272-278
- Lohrer H, Nauck T (2007) Endoscopically assisted release for exertional compartment syndromes of the lower leg. *Arch Orthop Trauma Surg* 127(9):827-834

- Loudon JK, Dolphino MR (2010) Use of foot orthoses and calf stretching for individuals with medial tibial stress syndrome. *Foot Ankle Spec* 3(1):15-20
- Love JW, Whelan TJ (1965) Popliteal artery entrapment syndrome. *Am J Surg* 109:620-624
- Lundvall J, Mellander S, Westing H, White T (1972) Fluid transfer between blood and tissues during exercise. *Acta Physiol Scand* 85(2):258-269
- Magnusson HI, Westlin NE, Nyqvist F, Gardsell P, Seeman E, Karlsson MK (2001) Abnormally decreased regional bone density in athletes with medial tibial stress syndrome. *Am J Sports Med* 29(6):712-715
- Matheson GO, Clement DB, McKenzie DC, Taunton JE, Lloyd-Smith DR, MacIntyre JG (1987) Stress fractures in athletes. A study of 320 cases. *Am J Sports Med* 15(1):46-58
- Marilla KT, Komu ME, Dahlstrom S, Koskinen SK, Heikkila J (1999) Medial tibial pain: a dynamic contrast-enhanced MRI study. *Magn Reson Imaging* 17(7):947-954
- Mavor GE (1956) The anterior tibial syndrome. *J Bone Joint Surg Br* 38-B(2):513-517
- McCrory P (2000) Exercise-related leg pain: neurological perspective. *Med Sci Sports Exerc* 32(3 Suppl):S11-S14
- McDermott AG, Marble AE, Yabsley RH, Phillips MB (1982) Monitoring dynamic anterior compartment pressures during exercise. A new technique using the STTC catheter. *Am J Sports Med* 10(2):83-89
- McDonald AT, Seidenberg PH, Noll D, Watson JT, Kieffer DA, O'Connor FG (2006) Bilateral forearm pain in an equestrian rider. *MSSE* 38(5):S161
- Meier TO, Schneider E, Amann-Vesti B (2010) Long-term follow-up of patients with popliteal artery entrapment syndrome treated by endoluminal revascularization. *Vasa* 39(2):189-195
- Messier SP, Pittala KA (1988) Etiologic factors associated with selected running injuries. *Med Sci Sports Exerc* 20(5):501-505
- Meyer SA, Salzman CL, Albright JP (1993) Stress fractures of the foot and leg. *Clin Sports Med* 12(2):395-413
- Michael RH, Holder LE (1985) The soleus syndrome. A cause of medial tibial stress (shin splints). *Am J Sports Med* 13(2):87-94
- Micheli LJ, Solomon R, Solomon J, Plasschaert VF, Mitchell R (1999) Surgical treatment for chronic lower-leg compartment syndrome in young female athletes. *Am J Sports Med* 27(2):197-201
- Milgrom C, Giladi M, Simkin A, Rand N, Kedem R, Kashan H, Stein M, Gomori M (1989) The area moment of inertia of the tibia: a risk factor for stress fractures. *J Biomech* 22(11-12):1243-1248
- Moen MH, Bongers T, Bakker EW, Weir A, Zimmermann WO, van der Werwe M, Backx FJ (2010) The additional value of a pneumatic leg brace in the treatment of recruits with medial tibial stress syndrome: a randomized study. *J R Army Med Corps* 156(4):236-240
- Moen MH, Bongers T, Bakker EW, Zimmermann WO, Weir A, Tol JL, Backx FJ (2012a) Risk factors and prognostic indicators for medial tibial stress syndrome. *Scand J Med Sci Sports* 22(1):34-39
- Moen MH, Rayer S, Schipper M, Schmitt S, Weir A, Tol JL, Backx FJ (2012b) Shockwave treatment for medial tibial stress syndrome in athletes: a prospective controlled study. *Br J Sports Med* 46(4):253-257
- Mohler LR, Sivf JR, Pedowitz RA, Hargens AR, Gershuni DH (1997) Intramuscular deoxygenation during exercise in patients who have chronic anterior compartment syndrome of the leg. *J Bone Joint Surg Am* 79(6):844-849
- Mollon B, da Silva V, Busse JW, Einhorn TA, Bhandari M (2008) Electrical stimulation for long-bone fracture-healing: a meta-analysis of randomized controlled trials. *J Bone Joint Surg Am* 90(11):2322-2330
- Mubarak SI, Hargens AR, Owen CA, Garetto LP, Akesson WH (1976) The wick catheter technique for measurement of intramuscular pressure. A new research and clinical tool. *J Bone Joint Surg Am* 58(7):1016-1020
- Mubarak SI, Gould RN, Lee YF, Schmidt DA, Hargens AR (1982) The medial tibial stress syndrome. A cause of shin splints. *Am J Sports Med* 10(4):201-205



- Nissen LR, Astvad K, Madsen L (1994) Low-energy laser therapy in medial tibial stress syndrome. *Ugeskr Laeger* 156(49):7329-7331
- Ohta-Fukushima M, Mutoh Y, Takasugi S, Iwata H, Ishii S (2002) Characteristics of stress fractures in young athletes under 20 years. *J Sports Med Phys Fitness* 42(2):198-206
- Orava S, Kapakka J, Huikko A, Vaananen K, Takala T, Kallinen M, Alen M (1991) Diagnosis and treatment of stress fractures located at the mid-tibial shaft in athletes. *Int J Sports Med* 12(4):419-422
- Ota Y, Senda M, Hashizume H, Inoue H (1999) Chronic compartment syndrome of the lower leg: a new diagnostic method using near-infrared spectroscopy and a new technique of endoscopic fasciotomy. *Arthroscopy* 15(4):439-443
- Paik RS, Pepples D, Hutchinson MR (2013) Chronic exertional compartment syndrome. *BMJ* 346:f33
- Pedowitz RA, Hagens AR, Mubarak SJ, Gershuni DH (1990) Modified criteria for the objective diagnosis of chronic compartment syndrome of the leg. *Am J Sports Med* 18(1):35-40
- Pham TT, Kapur R, Harwood MI (2007) Exertional leg pain: teasing out arterial entrapments. *Curr Sports Med Rep* 6(6):371-375
- Plisky MS, Rauh MJ, Heidenscheidt B, Underwood FB, Tank RT (2007) Medial tibial stress syndrome in high school cross-country runners: incidence and risk factors. *J Orthop Sports Phys Ther* 37(2):40-47
- Puranen J (1974) The medial tibial syndrome: exercise ischaemia in the medial fascial compartment of the leg. *J Bone Joint Surg Br* 56-B(4):712-715
- Reinking MF (2006) Exercise-related leg pain in female collegiate athletes: the influence of intrinsic and extrinsic factors. *Am J Sports Med* 34(9):1500-1507
- Rich NM, Collins GJ Jr, McDonald PT, Kozloff L, Clagett GP, Collins JT (1979) Popliteal vascular entrapment. Its increasing interest. *Arch Surg* 114(12):1377-1384
- Roberts A, Franklyn-Miller A (2012) The validity of the diagnostic criteria used in chronic exertional compartment syndrome: a systematic review. *Scand J Med Sci Sports* 22:585-595
- Rome K, Handoll HH, Ashford R (2005) Interventions for preventing and treating stress fractures and stress reactions of bone of the lower limbs in young adults. *Cochrane Database Syst Rev* (2):CD000450
- Rompe JD, Cacchio A, Furia JP, Maffulli N (2010) Low-energy extracorporeal shock wave therapy as a treatment for medial tibial stress syndrome. *Am J Sports Med* 38(1):125-132
- Rorabeck CH, Castle GS, Hardie R, Logan J (1981) Compartmental pressure measurements: an experimental investigation using the slit catheter. *J Trauma* 21(6):446-449
- Rupani HD, Holder LE, Espinola DA, Engin SI (1985) Three-phase radionuclide bone imaging in sports medicine. *Radiology* 156(1):187-196
- Saxena A, O'Brien T, Bunce D (1990) Anatomical dissection of the tibia's posterior muscle and its correlation to medial tibial stress syndrome. *J Foot Surg* 29(2):105-108
- Shaffer SW, Uhl TL (2006) Preventing and treating lower extremity stress reactions and fractures in adults. *J Athl Train* 41(4):466-469
- Stimmom D, Bennell K, Brukner P, Crossley K, Bell SN (2002) Long-term outcome of fasciotomy with partial fasciotomy for chronic exertional compartment syndrome of the lower leg. *Am J Sports Med* 30(4):581-588
- Slocum DB (1967) The shin splint syndrome. Medical aspects and differential diagnosis. *Am J Surg* 114(6):875-881
- Sommer HM, Vallenyne SW (1995) Effect of foot posture on the incidence of medial tibial stress syndrome. *Med Sci Sports Exerc* 27(6):800-804
- Stager A, Clement D (1999) Popliteal artery entrapment syndrome. *Sports Med* 28(1):61-70
- Stickley CD, Hetzler RK, Kimura IF, Lozano S (2009) Crural fascia and muscle origins related to medial tibial stress syndrome symptom location. *Med Sci Sports Exerc* 41(11):1991-1996
- Syvf J (1988) Diagnosis of exercise-induced pain in the anterior aspect of the lower leg. *Am J Sports Med* 16(2):165-169
- Syvf JR, Körner LM (1986) Microcapillary infusion technique for measurement of intramuscular pressure during exercise. *Clin Orthop Relat Res* June (207):253-262

- Swenson EJ Jr, DeHaven KE, Sebastianelli WJ, Hanks G, Kalenak A, Lynch JM (1997) The effect of a pneumatic leg brace on return to play in athletes with tibial stress fractures. *Am J Sports Med* 25(3):322-328
- Touliopoulos S, Hersham EB (1999) Lower leg pain. Diagnosis and treatment of compartment syndromes and other pain syndromes of the leg. *Sports Med* 27(3):193-204
- Tunipseed WD (2009) Functional popliteal artery entrapment syndrome: a poorly understood and often missed diagnosis that is frequently misread. *J Vasc Surg* 49(5):1189-1195
- van den Brand JG, Verleisdonk EJ, van der Werken C (2004) Near infrared spectroscopy in the diagnosis of chronic exertional compartment syndrome. *Am J Sports Med* 32(2):452-456
- van Zoest WJ, Hoogveen AR, Scheeltinga MR, Sala HA, van Mourik JB, Brink PR (2008) Chronic deep posterior compartment syndrome of the leg in athletes: postoperative results of fasciotomy. *Int J Sports Med* 29(5):419-423
- Veith RI, Matsen FA, Newell SG (1980) Recurrent anterior compartmental syndromes. *Phys Sportsmed* 8(11):80-88
- Verleisdonk EJ (2002) The exertional compartment syndrome: a review of the literature. *Orthop Traumatol Rehabil* 4(5):626-631
- Verleisdonk EJ, van Gils A, van der Werken C (2001) The diagnostic value of MRI scans for the diagnosis of chronic exertional compartment syndrome of the lower leg. *Skeletal Radiol* 30(6):321-325
- Vithasalo JT, Kvist M (1983) Some biomechanical aspects of the foot and ankle in athletes with and without shin splints. *Am J Sports Med* 11(3):125-130
- Wallensten R (1983) Results of fasciotomy in patients with medial tibial syndrome or chronic anterior-compartment syndrome. *J Bone Joint Surg Am* 65(9):1252-1255
- Wheeler P, Batt ME (2005) Do non-steroidal anti-inflammatory drugs adversely affect stress fracture healing? A short review. *Br J Sports Med* 39(2):65-69
- Whitesides TE, Heckman MM (1996) Acute compartment syndrome: update on diagnosis and treatment. *J Am Acad Orthop Surg* 4(4):209-218
- Whitesides TE, Haney TC, Morimoto K, Harada H (1975) Tissue pressure measurements as a determinant for the need of fasciotomy. *Clin Orthop Relat Res* Nov-Dec (113):43-51
- Witstein J, Moorman CT 3rd, Levin LS (2010) Endoscopic compartment release for chronic exertional compartment syndrome: surgical technique and results. *Am J Sports Med* 38(8):1661-1666
- Yates B, White S (2004) The incidence and risk factors in the development of medial tibial stress syndrome among naval recruits. *Am J Sports Med* 32(3):772-780
- Zhang Q, Lindberg LG, Kadefors R, Syvf J (2001) A non-invasive measure of changes in blood flow in the human anterior tibial muscle. *Eur J Appl Physiol* 84(5):448-452
- Zhang Q, Jonasson C, Syvf J (2011) Simultaneous intramuscular pressure and surface electromyography measurement in diagnosing the chronic compartment syndrome. *Scand J Med Sci Sports* 21:190-195
- Zhang Q, Rennefelt K, Syvf J (2012) The magnitude of intramuscular deoxygenation during exercise is an unreliable measure to diagnose the cause of leg pain. *Scand J Med Sci Sports* 22:690-694
- Zimmermann WO (2012) Developments in the treatment of chronic exertional compartment syndrome. *Nederl Mil Geneesk T Sep* (65):160-162
- Zimmermann WO (2013a) Sports compression stockings: the effect on the running performance of 100 soldiers with an overuse injury of the lower legs. *Nederl Mil Geneesk T Jan* 66:11-17
- Zimmermann WO (2013b) Chronic overuse injuries of the legs in military personnel: new findings in the soft tissues? *Nederl Mil Geneesk T July* 66:92-98